



Emergency angio-embolisation in the operating theatre for trauma patients using the C-Arm digital subtraction angiography

Li Tserng Teo^{a,*}, S. Punamiya^b, C.Y. Chai^a, K.T.S. Go^a, Y.T. Yeo^a, D. Wong^b,
V. Appasamy^a, M.T. Chiu^a

^aTrauma Services, Department of General Surgery, Tan Tock Seng Hospital, Singapore

^bInterventional Radiology, Department of Radiology, Tan Tock Seng Hospital, Singapore

ARTICLE INFO

Article history:

Accepted 24 January 2011

Keywords:

Emergency angio-embolisation
C-Arm DSA
Damage control/resuscitation
Mobile hybrid trauma operating theatre

ABSTRACT

Background and aims: Angio-embolisation in trauma is a relatively new technique that is gaining popularity and recognition in identifying and arresting bleeding in trauma patients. We studied the possibility whether angio-embolisation using the Digital Subtraction Angiography (DSA), in the operating theatre (OT) could achieve successful haemostasis in trauma patients. We further studied the feasibility of using this technique as part of trauma resuscitation/damage control. **Methods:** A retrospective study of trauma patients, with Injury Severity Score (ISS ≥ 9), admitted to Tan Tock Seng Hospital (TTSH) from January 2004 to December 2008 was done. Patients who had received angio-embolisation in the OT or angiography suite were evaluated in terms of age, gender, ISS, the site and type of angioembolisation used. The primary end point was to assess the success rate of angioembolisation using the C-Arm DSA in the OT, and whether there were any complications necessitating a repeat procedure or surgical intervention. The secondary end points of the study were aimed at studying the cost effectiveness of this technique, logistical feasibility and evaluating this technique as part of the initial trauma resuscitative efforts. **Results:** A total of 43 trauma patients received angioembolisation. 32 patients had the angio-embolisation done using the C-Arm DSA in the OT ($n = 32$). None of the patients who received angioembolisation in the operating theatre ($n = 32$) had any re-bleeding. 15 out of 32 survived. There were no complications related to the angio-embolisation procedure. The majority of angio-embolisations done were for pelvic fractures. **Conclusion:** The success of angio-embolisation in the OT using the C-Arm DSA for a trauma patient and its complication rates are similar to that done in a dedicated angio-graphic suite. We conclude that angio-embolisation in the operating theatre using the C-Arm DSA is feasible, cost effective and can be a modality in the initial trauma resuscitation/damage control in any lead lined operating theatre. We believe that we are the first to describe this method of angio-embolisation using the C-Arm DSA in a conventional lead lined trauma operating theatre and its use as a feasible option in a trauma resuscitation/damage control algorithm.

© 2011 Elsevier Ltd. All rights reserved.

Introduction

Traumatic injury is the leading cause of death worldwide amongst persons aged 5–44 years old,⁸ and accounts for 10% of all deaths.⁹ Despite improvements in trauma care, uncontrolled bleeding still contributes to 30–40% of all deaths and is the leading cause of potentially preventable early in-hospital deaths.^{5,6,10}

Angio-embolisation, as a modality in arresting ongoing haemorrhage in trauma patients, is a relatively new concept which is increasingly gaining recognition.^{1,3} Currently majority of angio-embolisations are done in a specialised angiography suite,^{2,7}

which may or may not have the capability of a trauma operating theatre (OT).

Tan Tock Seng Hospital (TTSH) is the busiest acute care hospital and 2nd largest hospital in Singapore. We started performing angio-embolisation of trauma patients who had evidence (clinical or radiological) of ongoing arterial bleeding since 2004. In addition to this, we also started doing it in a standard trauma OT, using a C-Arm image intensifier with Digital Subtraction Angiography (C-Arm DSA), as part of trauma resuscitation and/or damage control surgery for patients who were haemodynamically unstable.

Aim

The aim of this retrospective study was to describe and evaluate the feasibility of using the C-Arm DSA, in a standard lead lined

* Corresponding author.

E-mail addresses: li_tserng_teo@ttsh.com.sg, teolitserng@yahoo.com (L.T. Teo).

trauma OT, to angio-embolise trauma patients with active arterial bleeding. We wanted to evaluate whether this angio-embolisation technique could achieve radiological and haemodynamic success, with comparable complication rates to conventional angio-embolisation in a dedicated angiographic suite. The secondary aim was to evaluate the feasibility of using this technique as part of the initial trauma resuscitation of a haemodynamically unstable patient.

Method

A retrospective study of all trauma patients who required any form of angio-embolisation from 1st January 2004 to 31st December 2008 was performed. Patient data was obtained from the hospital's trauma registry and medical records.

Exclusion criteria included patients who had angio-embolisation done in the angiography suite, patients for whom angiography was incomplete, patients who died before angio-embolisation was attempted and patients who had incomplete medical records with regards to the angio-embolisation procedure.

We studied the epidemiology, Injury Severity Score (ISS), duration of the angio-embolisation, radiological success of angio-embolisation and complications as a result of the angio-embolisation procedure. Mortality rates were also studied.

Results

A total of 4888 trauma patients with $ISS \geq 9$ were admitted to TTSH between January 2004 and December 2008. 43 of these patients received angio-embolisation haemorrhage control.

32 of these patients had angio-embolisation done in the emergency operating theatre using the C-Arm DSA as part of trauma resuscitation/damage control (Table 1).

65.6% of patients had an ISS of greater than 40. The mean ISS was 45.28.

All patients had radiological evidence of active arterial bleeding either via a pre procedure trauma CT scan or an on-table angiography using the C-Arm. The most common site of angio-embolisation was the pelvic vessels (26 out of 32 patients). The rest received angio-embolisation to the hepatic vessels (5/32) and one patient had ilio-lumbar vessels angio-embolised. These angio-embolisation procedures were described to be that of selective angio-embolisation (Fig. 1).

The angio-embolisation techniques and materials used for the angio-embolisation were similar to what would have been used if the procedure was done in a dedicated, specialised angiography suite. Coils and gel foams were used. The procedure of angio-embolisation itself was done by 2 interventional radiologists for all patients (Fig. 2).

All 32 patients had radiological and angiographic confirmation of successful haemostasis post angio-embolisation. This was subsequently correlated with an improvement in the physiological state of the patients. In addition, 20 out of 26 patients with pelvic

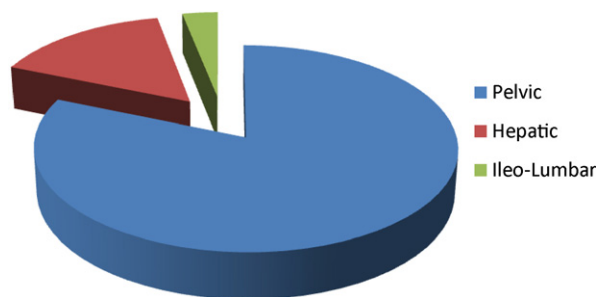


Fig. 1. Site of angio-embolisation.

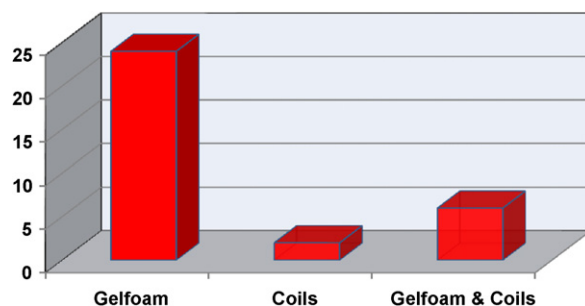


Fig. 2. Method of angio-embolisation.

fractures had a pelvic external fixator applied within 30 min pre/post angio-embolisation. 6 out of 32 patients had damage control laparotomy pre-angioembolisation. The mean time between laparotomy and start of angio-embolisation was 12 min.

All angio-embolisations using the C-Arm were started within 56 min of admission to hospital. Mean time taken for the completion of the angio-embolisation procedures was 34 min. The time taken for the angio-embolisation was defined as time of first cannulation to the time of the completion angiography post angio-embolisation.

There were no complications post angio-embolisation related to the procedure.

15 of the 32 patients survived. The cause of the mortalities were not related to uncontrolled haemorrhage but related to the severity of the traumatic insult as per suggested by the coroner's reports (Fig. 3).

Half of the survivors stayed in hospital for more than 50 days.

Discussion

Angio-embolisation in trauma has added to our armamentarium in managing patients with life threatening traumatic bleeding since the 1970s. However, this is a relatively new method in managing trauma patients and not many centres are equipped with sophisticated angiographic set-ups to provide such an intervention.

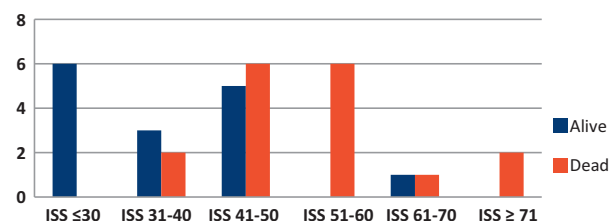


Fig. 3. Relation of ISS to outcome of those who received angioembolisation in the operating theatre.

Table 1

Summary of patient characteristics.

Mean age	39.53
Mean ISS	45.28 (SD ± 15.29)
Sex	
Male	21
Female	11
Mechanism of injury	
Road traffic accident	21
High impact falls	10
Median length of stay (days)	8.5
Mortality	17
Morbidity	0

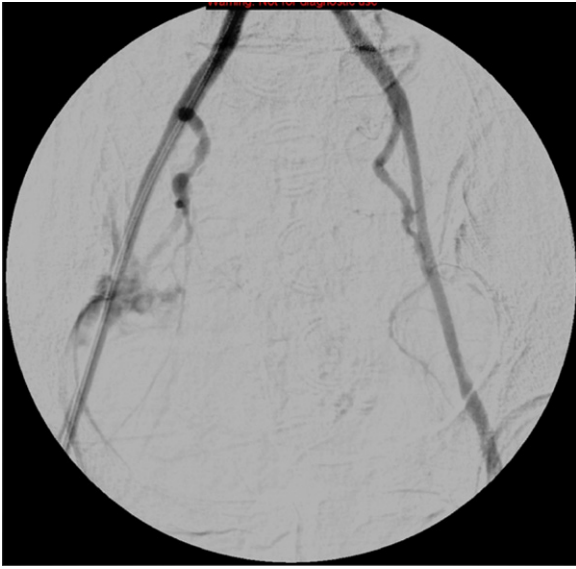


Image 1. C-Arm DSA image (in trauma OT) showing active extravasation of contrast from the anterior division of the right internal iliac artery).

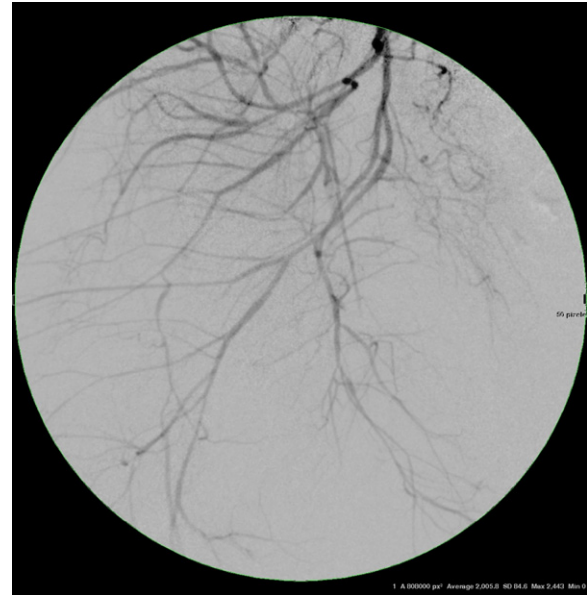

Image 2. Pelvic Angiogram using C-Arm DSA.

In TTSH, we have both the C-Arm DSA capability and 2 state of the art angiography suites. The C Arm DSAs used in this study were either the Siemens[®] Arcadis Varic or the Phillips[®] BV Endora (approximate cost being S\$170,000). The state-of-the-art angiography suite with anaesthetic capability costs approximately S\$3 million per suite to set up.

Our study has shown that the success of angio-embolisation, though multi-factorial, is not determined by the type of equipment used nor the place (angiography suite or lead lined OT) that the procedure is done in.⁷ We have shown that with the use of the C-Arm DSA in a standard lead lined OT, successful arterial haemostasis (confirmed by post angio-embolisation angiography) can be achieved with similar results. In angio-embolisations in an unstable trauma patient, the key to achieving successful haemorrhage control is not to do super-selective angio-embolisations but simply selective angio-embolisation of the errant vessel. With this key concept in mind, we were able to achieve the same results using the C-Arm DSA when compared with the cases done in a dedicated angiography suite. There was concern with performing selective angio-embolisation for hepatic vessels, instead of super selective angio-embolisation. Selective angio-embolisation has been described mainly for pelvic vessels. However, our experience, in this study and other solid organ angio-embolisations done in our centre, show that this is a safe method with minimal long term end organ damage. This method will be especially relevant when performing angio-embolisation as part of damage control/resuscitative efforts as shown in our study.

Our study challenges both the interventional radiologist and the surgeon to re-consider the mindset that emergency angio-embolisation procedures need to be done in a state of the art fully equipped angiography suite/angiography capable emergency OT in view of concerns about angiography image resolutions. We have shown that a simple C-Arm DSA can provide images of sufficient resolution for us to perform successful angio-embolisations of trauma patients (Image 1). Image 2 and Image 3 compares the resolutions, of a C-Arm DSA and that taken in the angio-suite, of the same trauma patient. This further illustrates that resolutions using the C-Arm DSA are acceptable. Super selective angio-embolisations have also been performed using the C-Arm DSA in selected cases. We conclude that radiographic image resolution/field of view obtained using the C-Arm DSA are sufficient/adequate enough for

our interventional radiologists to perform successful and safe selective/super selective angio-embolisations in a damage control/resuscitative effort (Table 2).

This finding will benefit centres that may not have the ability to set-up a multi-million dollar angiography suite. Any centre involved in orthopaedic surgery would have already purchased a standard C-Arm DSA thus making that centre capable of performing emergency angio-embolisations. There is no additional infra-structural set-up cost and this technique is an added capability of the C-Arm DSA.

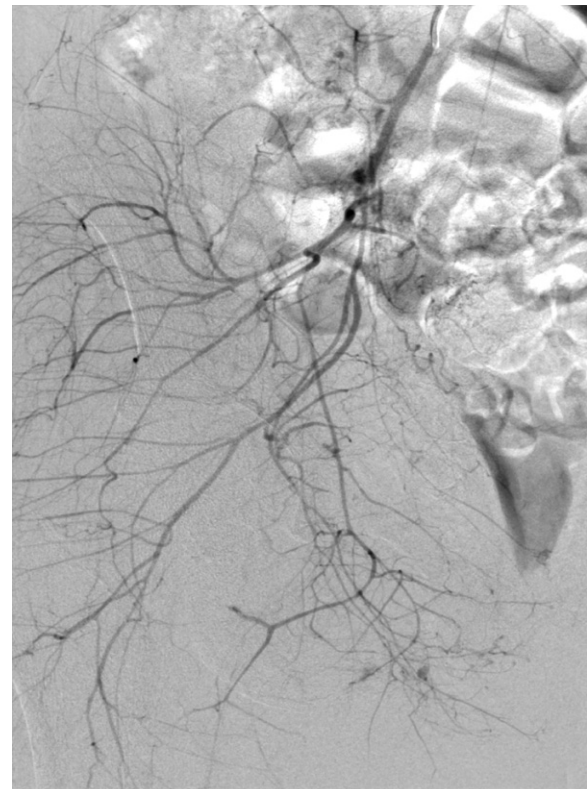


Image 3. Comparison Pelvic Angiogram in the angio-suite.

Table 2
Comparing C-Arm DSA and fixed angiography suite machines.

	Portable Angio unit (C-Arm DSA) (Siemens Arcadis Varic/ Philips BV Pulsera)	Fixed Angio unit	Comments
Quality of image	Adequate	Excellent	The Angio suite machine produces better quality images due to higher output X-ray generators, better X-ray tubes and superior image intensifier. This is most evident when performing procedures in obese patients. However, the C-Arm DSA achieves adequate image quality for emergency angio-embolisation.
Field of view (FOV)	Small to medium	Small to large	The large FOV of fixed Angio machine means more coverage in one angiogram. The higher magnification provided by the fixed unit enables more accurate embolisation. For selective angio-embolisations, the FOV of the C-Arm DSA is sufficient.
Special construction	None	Required	Portable equipment can be operated from any plug-point, not requiring special installation.
Portability	Yes	No	Portable unit can be moved quickly from one OT to another.
Cost	SGD 170,000	SGD 3,000,000	Any lead lined OT can be converted into an angiography capable trauma OT. Portable units are most cost efficient for non-selective embolisations.

However, we do acknowledge that individual preferences and initial reluctance by the interventional radiologist to use the C-Arm DSA for such procedures needs to be overcome. We are fortunate that our interventional radiologists at TTSH were quick to develop a certain comfort level in doing good quality angio-embolisation in the trauma OT using the C-Arm DSA (Pic. 1).

In this study, the ISS of patients who had angio-embolisation done in OT was high. This is due to the trauma unit's policy to carry out a trauma resuscitation (once the patient is stable enough to be transported to the OT) in the emergency OT. The angio-embolisation procedure is used as part of the trauma resuscitation instead of a pure treatment modality.⁷ For patients with a clinical suspicion of retro-peritoneal haemorrhage or pelvic haemorrhage, should they be haemodynamically unstable, an on-table angiography will be done with a view of angio-embolisation (prophylactic if required). This is done with the trauma surgeon being ready to perform a trauma laparotomy or damage control surgery.⁴ Our hospital's set-up would entail the interventional radiologist performing the angio-embolisation whilst the surgical team is ready to perform damage control surgery should the patient be too unstable to complete the initial angio-embolisation. We have performed damage control surgery in tandem (or within a short period of time, mean of 12 min) with the interventional radiologist doing the angio-embolisation. We believe that these encouraging results have provided us with an additional option to our algorithm in managing unstable trauma patients. In addition, we further propose that in the initial trauma resuscitation/damage control

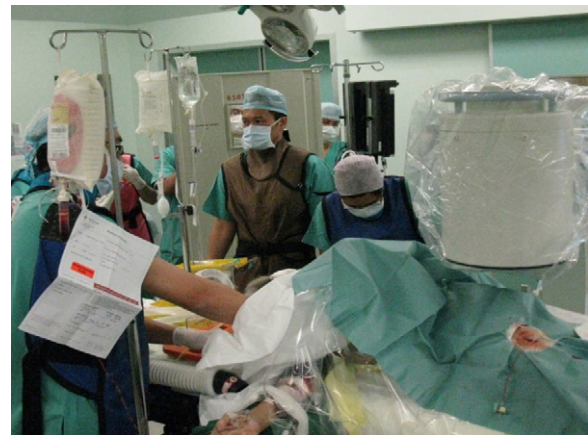

Fig. 2. Trauma resuscitation/laparotomy in tandem with C-Arm angio-embolisation in OT.

surgery, the interventional radiologist should have an equally immediate and important role (Pic. 2).

Having the capability of performing angio-embolisation in OT reduces the transport time from angiography suite to the emergency OT should they not be located in the same area or should either procedure not be able to be done in the same OT.

By using the mobile C-Arm DSA, we have been able to utilise any of our 13 lead lined OTs for trauma resuscitation/damage control, instead of being limited to using one of the 2 angio-suites or dedicated emergency static angio-capable OTs. This has resulted in a shorter time from time of arrival to time of angio-embolisation and expedited the management of our trauma patients.

It is also encouraging that the complication rate, in this study, for procedures done in the OT was nil. Complication rates are also similar to those reported, regardless of the location where the procedure is carried out. This again, affirms our belief that trauma angio-embolisation can be carried out successfully, safely and cost effectively using the C-Arm DSA.

We believe that this method of performing emergency angio-embolisation using the C Arm DSA for haemodynamically unstable patients may be the answer to the hybrid trauma OT with endovascular capability that would be ideal in managing unstable trauma cases.⁷ The advantage of this being a mobile unit, replicable in any lead lined OT, makes this technique feasible and exciting addition to our algorithm in managing unstable trauma patients.

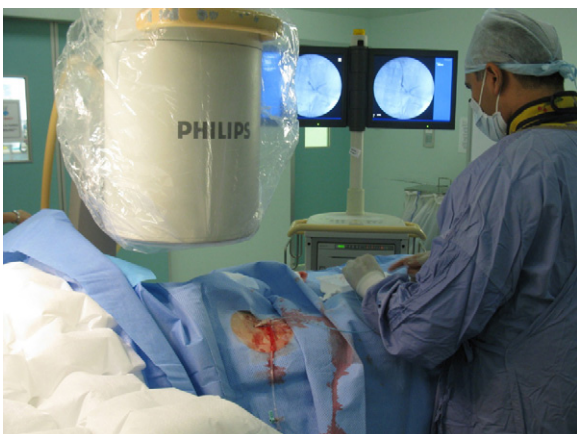

Fig. 1. Emergency trauma angio-embolisation using the C-Arm in lead lined OT.

Conclusion

Angio-embolisation in trauma has become a useful modality in the management of trauma patients. Our study showed that safe, successful and cost effective angio-embolisation in trauma patients can be carried out using the conventional C-Arm DSA and standard lead lined emergency OT. This is a feasible alternative to the potentially prohibitive set-up costs of a dedicated angiography suite. We further propose that such a set-up be considered as part of the immediate resuscitative efforts rather than as a treatment modality in the emergency OT. This set-up may be the first prototype of a mobile hybrid trauma operating theatre with endovascular capability. We believe we are the first to describe the use of the C Arm DSA for in theatre emergency angio-embolisation as part of the initial trauma resuscitation process.

Conflict of interest statement

The authors declare that there are no conflicts of interest with regards to the study.

References

1. Fangio P, Aselnoune K, Edouard A, et al. Early embolisation and vasopressor administration for management of life threatening haemorrhage from pelvic trauma. *J Trauma* 2005;58(5 (May)):978–84.
2. Gansslen A, Giannoudis P, Pape HC. Haemorrhage in pelvic fracture: who needs angiography? *Curr Opin Crit Care* 2003;9:515–23.
3. Geeraets T, Chlor V, Cheissen G, et al. Initial management of blunt pelvic trauma patients with haemodynamic instability. *Crit Care* 2007;11(1):204.
4. Grimm MR, Vrahas MS, Thomas KA. Pressure volume characteristics of the intact and disrupted pelvic retroperitoneum. *J Trauma* 1998;44:454–9.
5. Holcomb JB. Methods for improved haemorrhage control. *Crit Care* 2004;8(Suppl. 2):557–60.
6. Kanvar DS, Wade CF. The epidemiology and modern management of traumatic haemorrhage: US and international perspectives. *Crit Care* 2005;9(Suppl. 5): 51–9.
7. Karim Brohi. Management of exsanguinating pelvic injuries: an algorithm for the management of exsanguinating pelvic trauma. Available from: <http://trauma.org/index.php/main/article/668/>.
8. Krug EG, Sharma GK, Lozano R. The global burden of injuries. *Am J Public Health* 2000;90:523–6.
9. Murray CJ, Lopez AD. Mortality by cause for eight regions of the world: global burden of disease study. *Lancet* 1997;349:1269–76.
10. Sauaia A, Moore FA, Moore EE, et al. Epidemiology of trauma deaths: a reassessment. *J Trauma* 1995;38:185–93.